



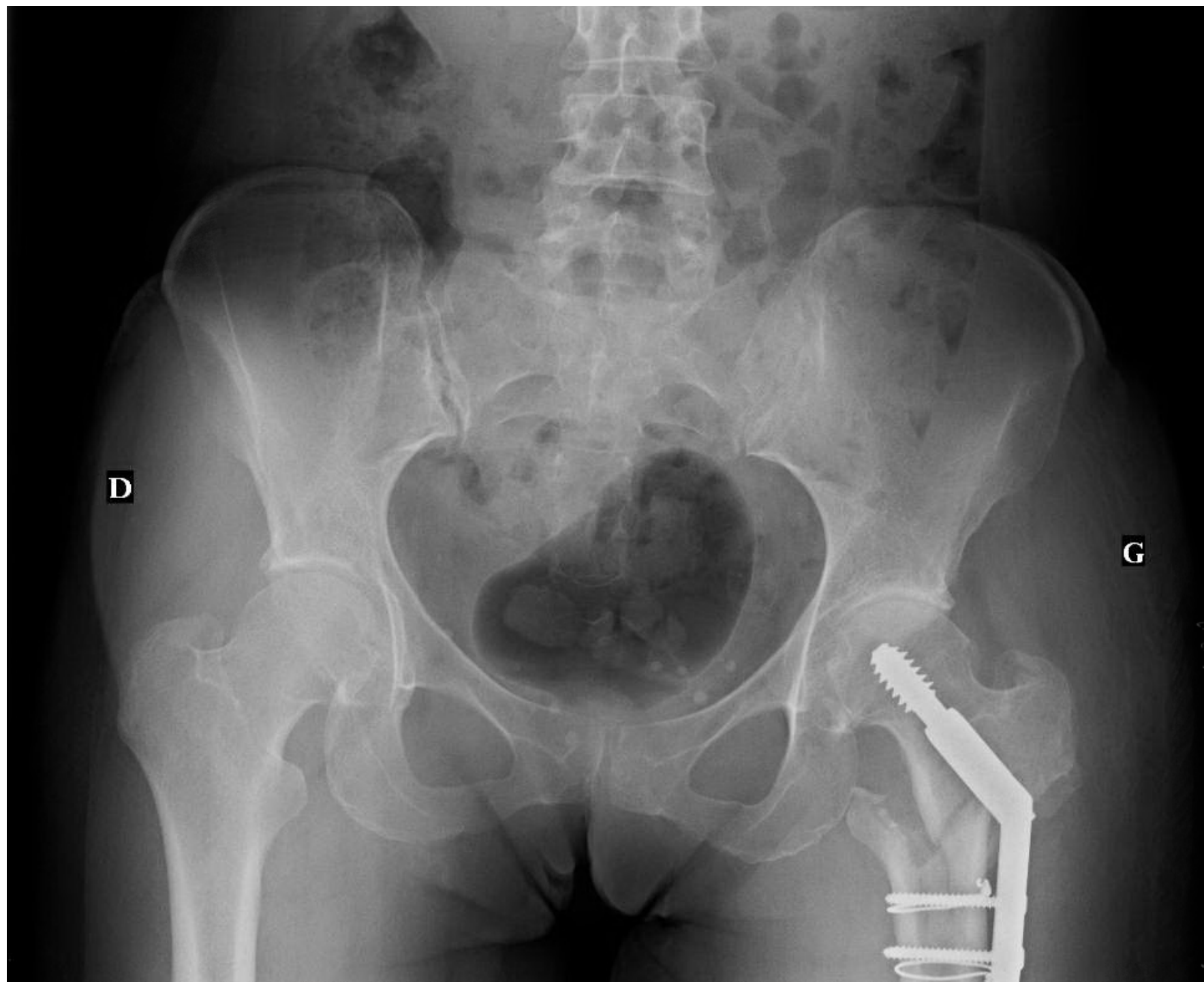
Case

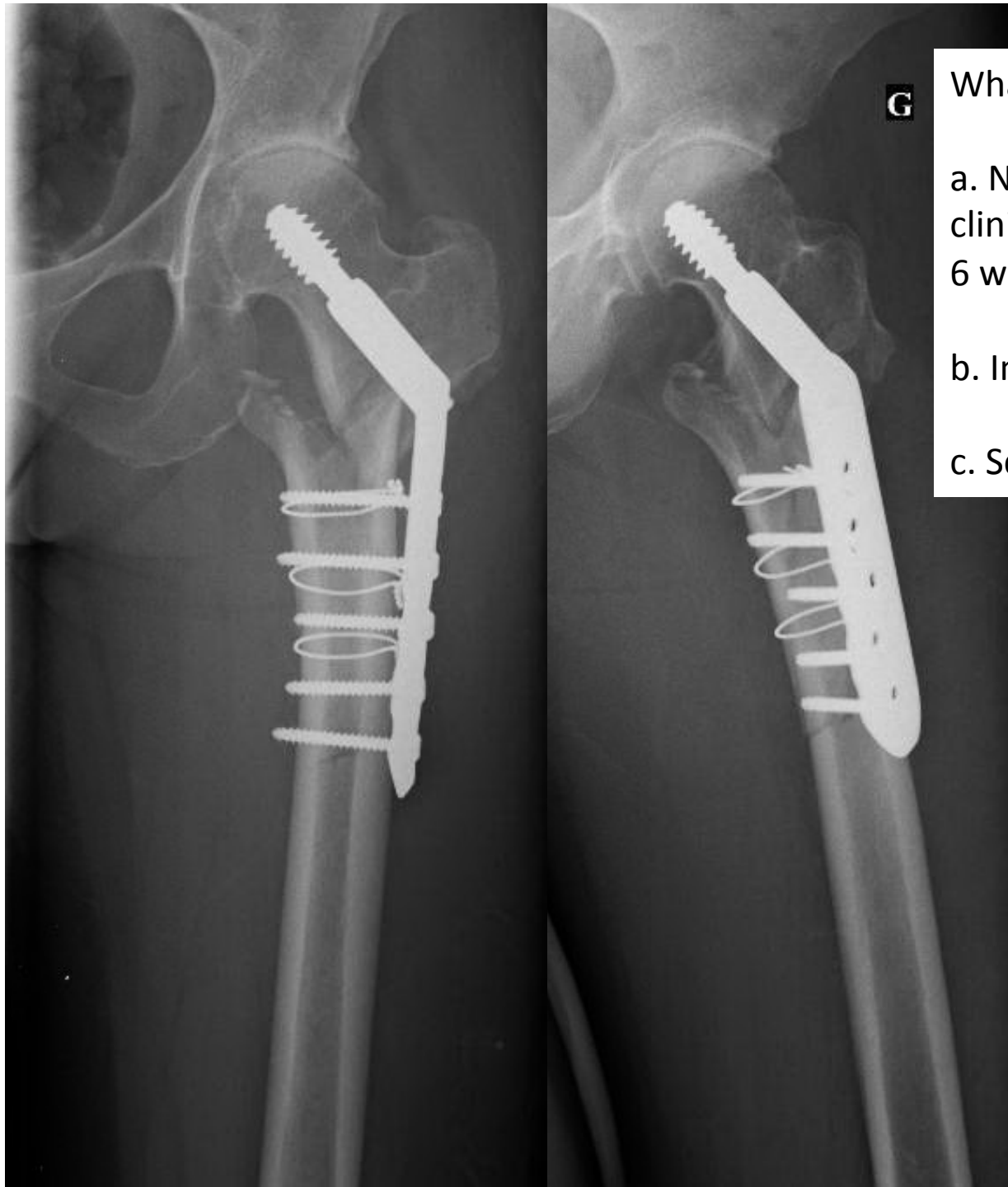Prof . Cornu



- Female 51 y.o.
- Very active / Sport +++
- Left hip arthritis – viscosupplementation
- Hip fracture 2 weeks ago in Mont Ventoux (bicycle fall)
- Follow up visit

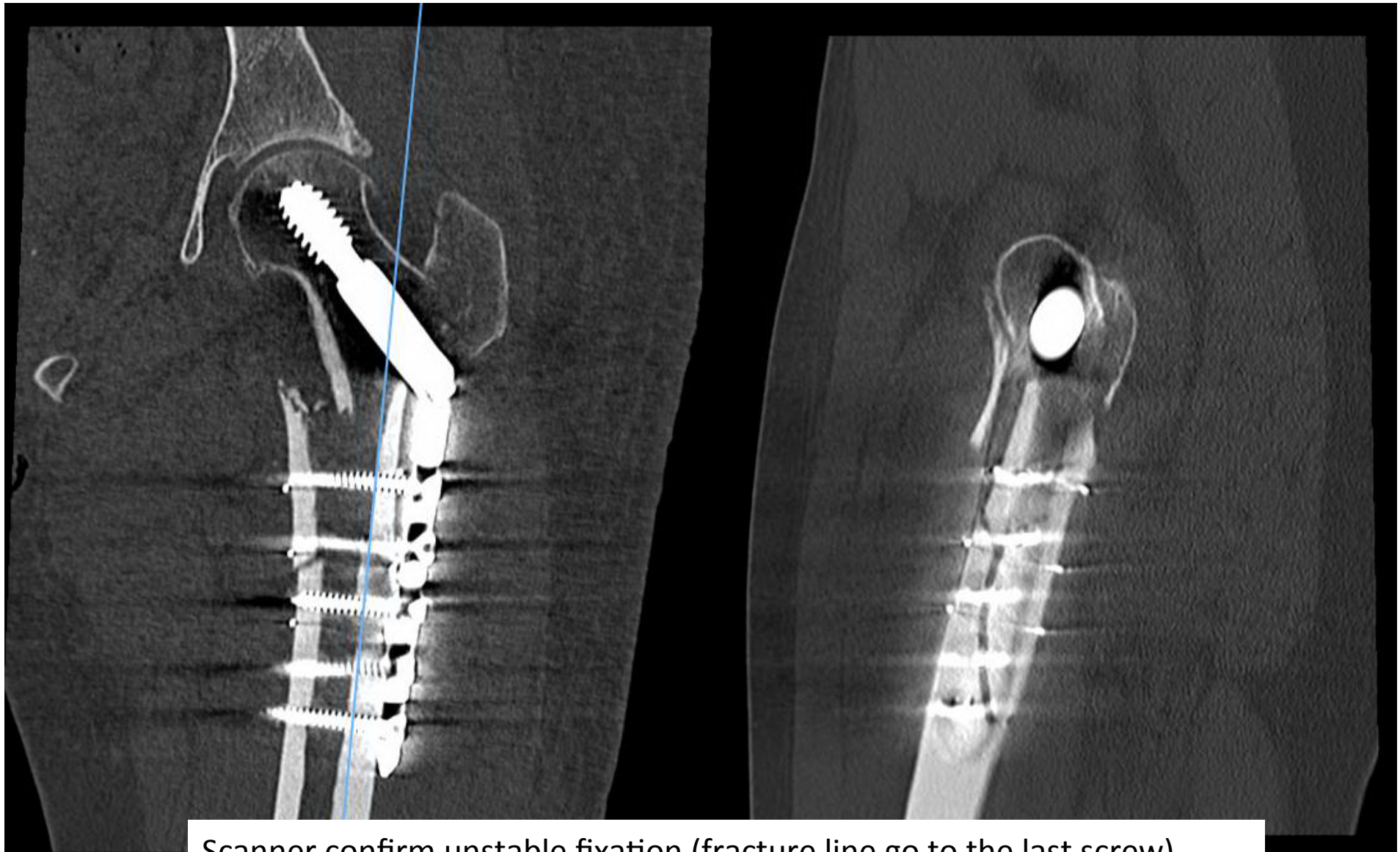





What do you perform ?

- a. Non weight bearing and clinical/radiographic follow up at 6 weeks
- b. Immediate surgical revision
- c. Scanner

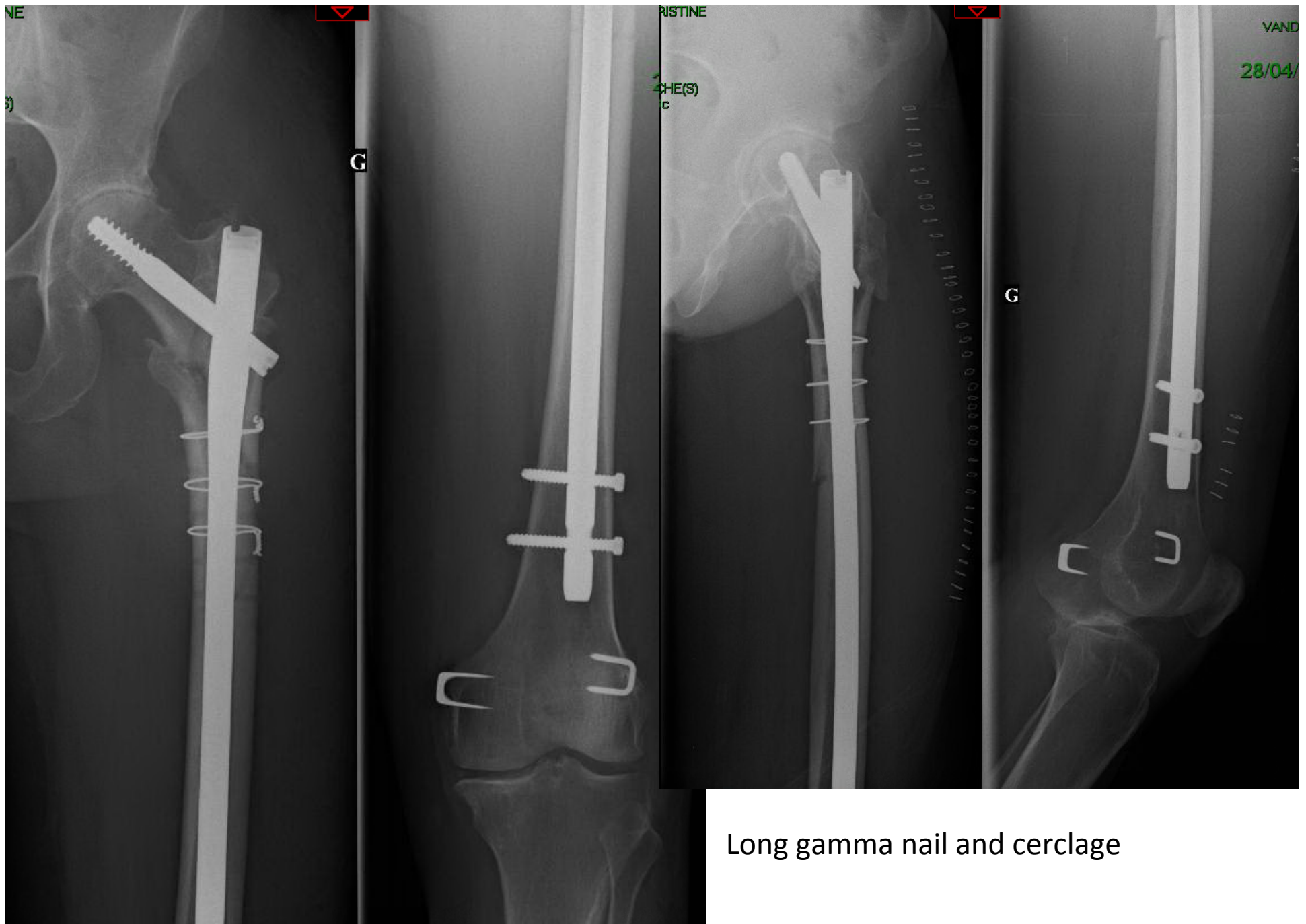

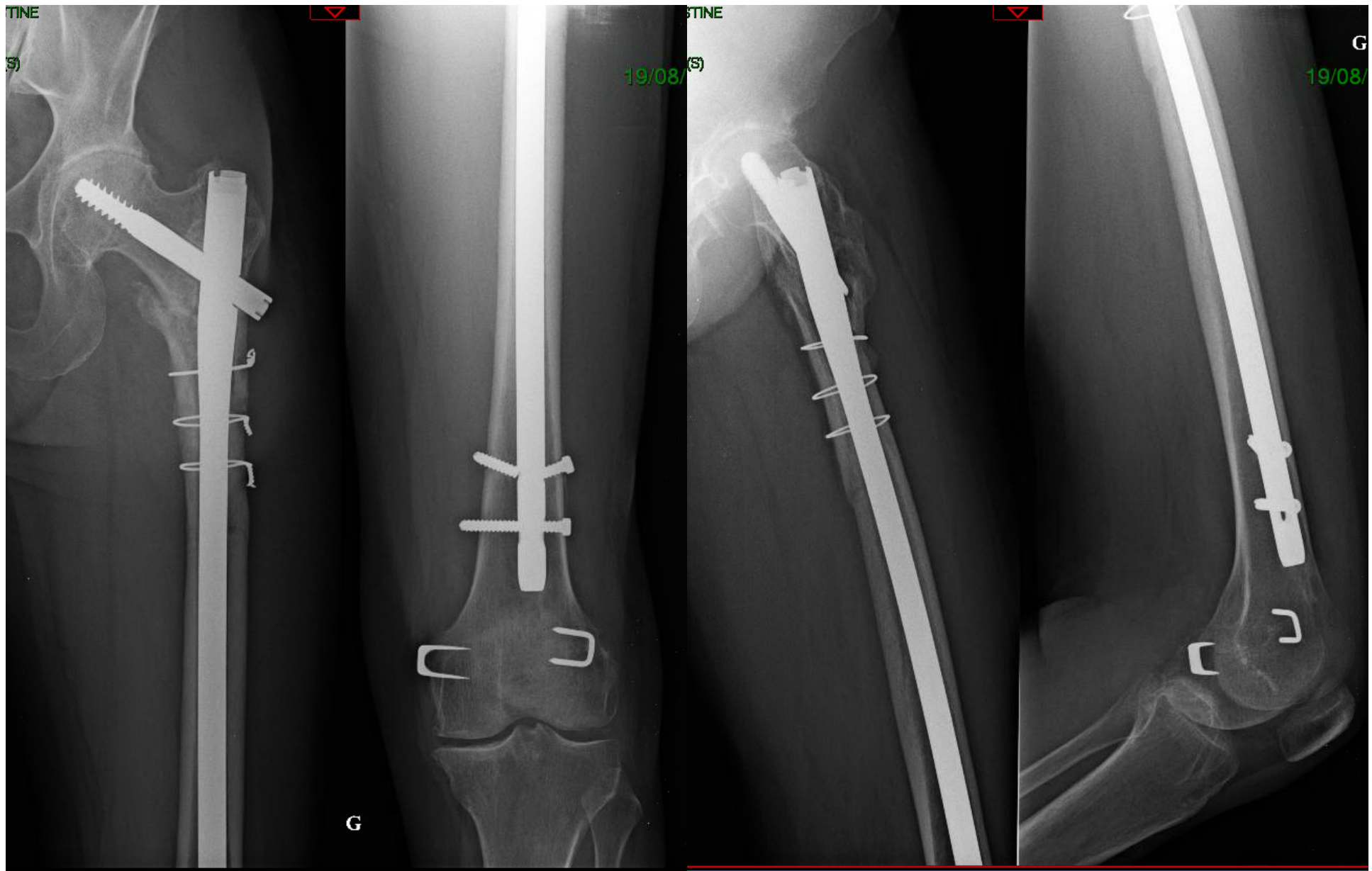
Scanner confirm unstable fixation (fracture line go to the last screw)

-> Decision for surgical revision

Which option do you choose ?

- a. Nail b. Longer plate c. Hip arthroplasty



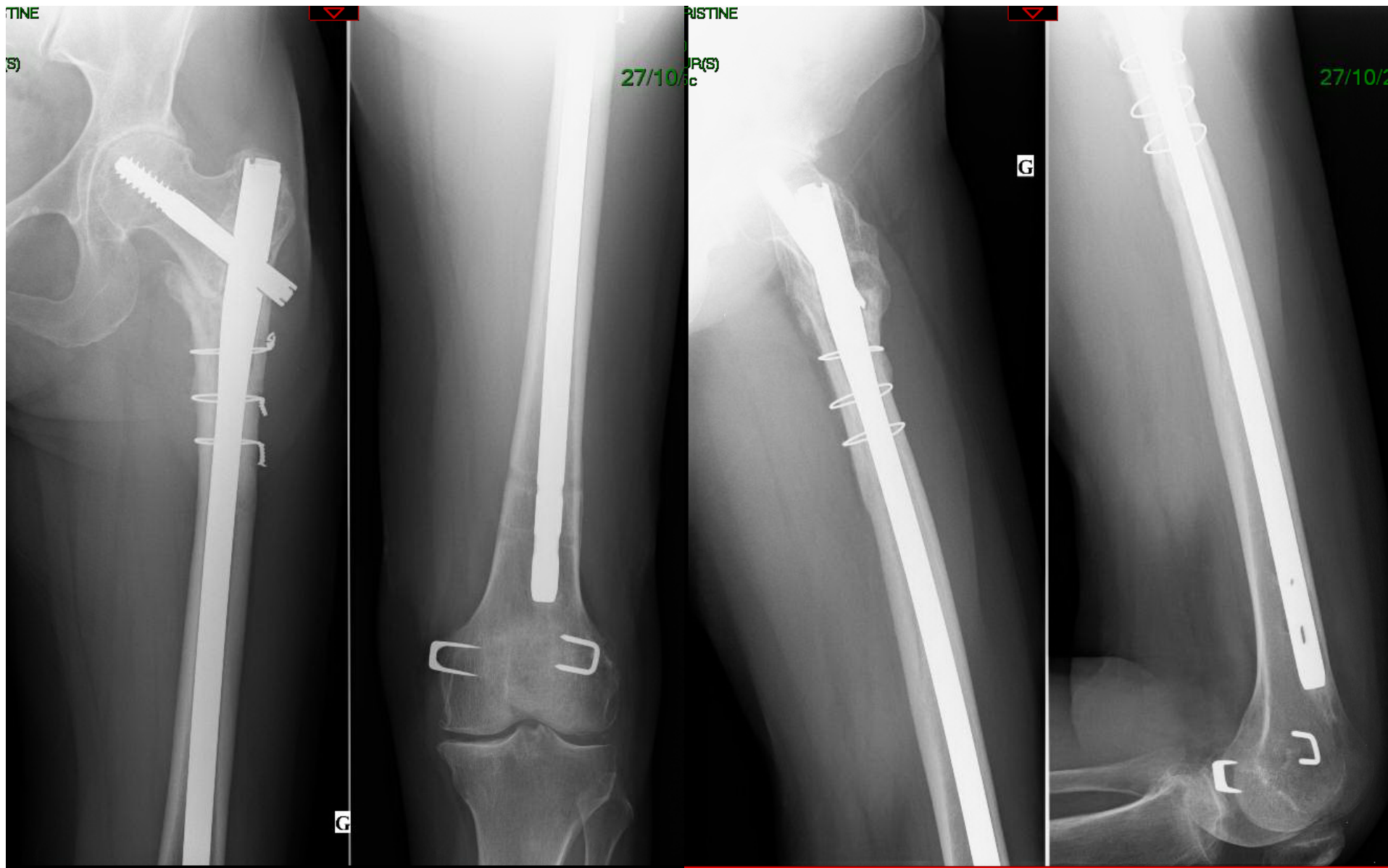

3 months after surgical revision ; one screw break ; shortening 1 cm

What do you perform ? a. Wait and see

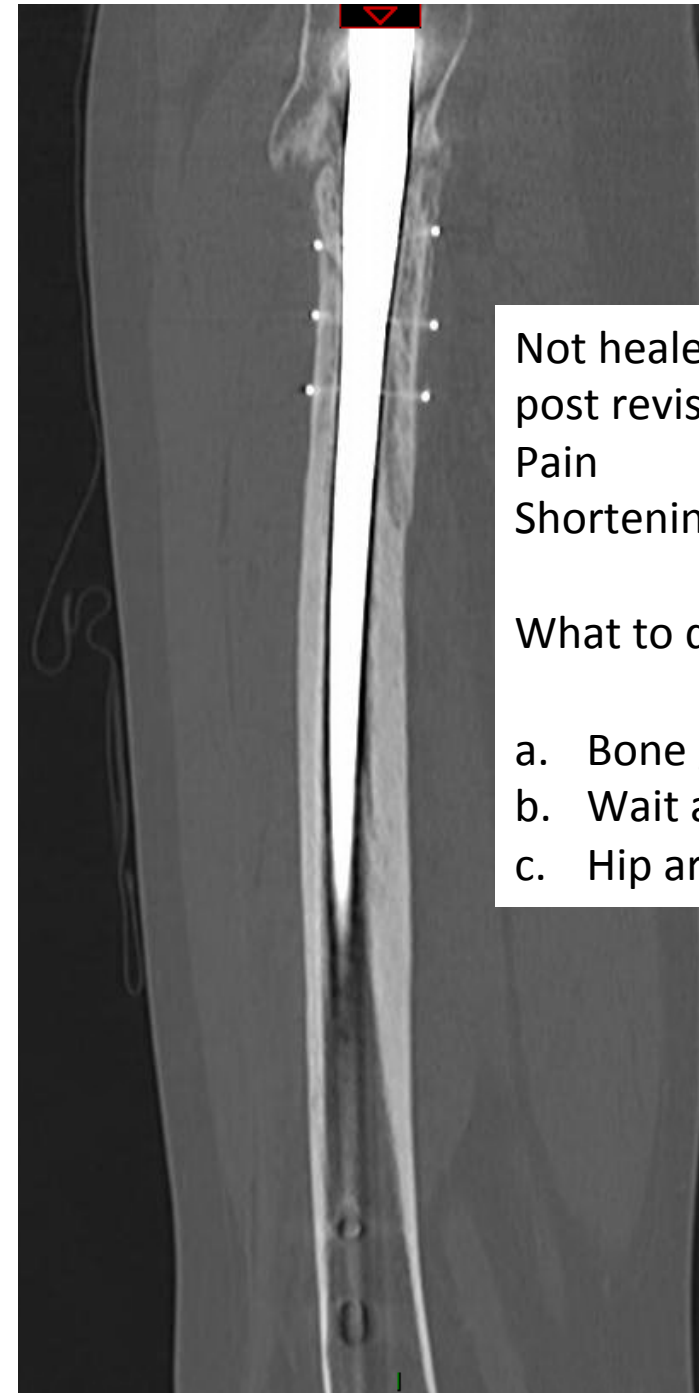
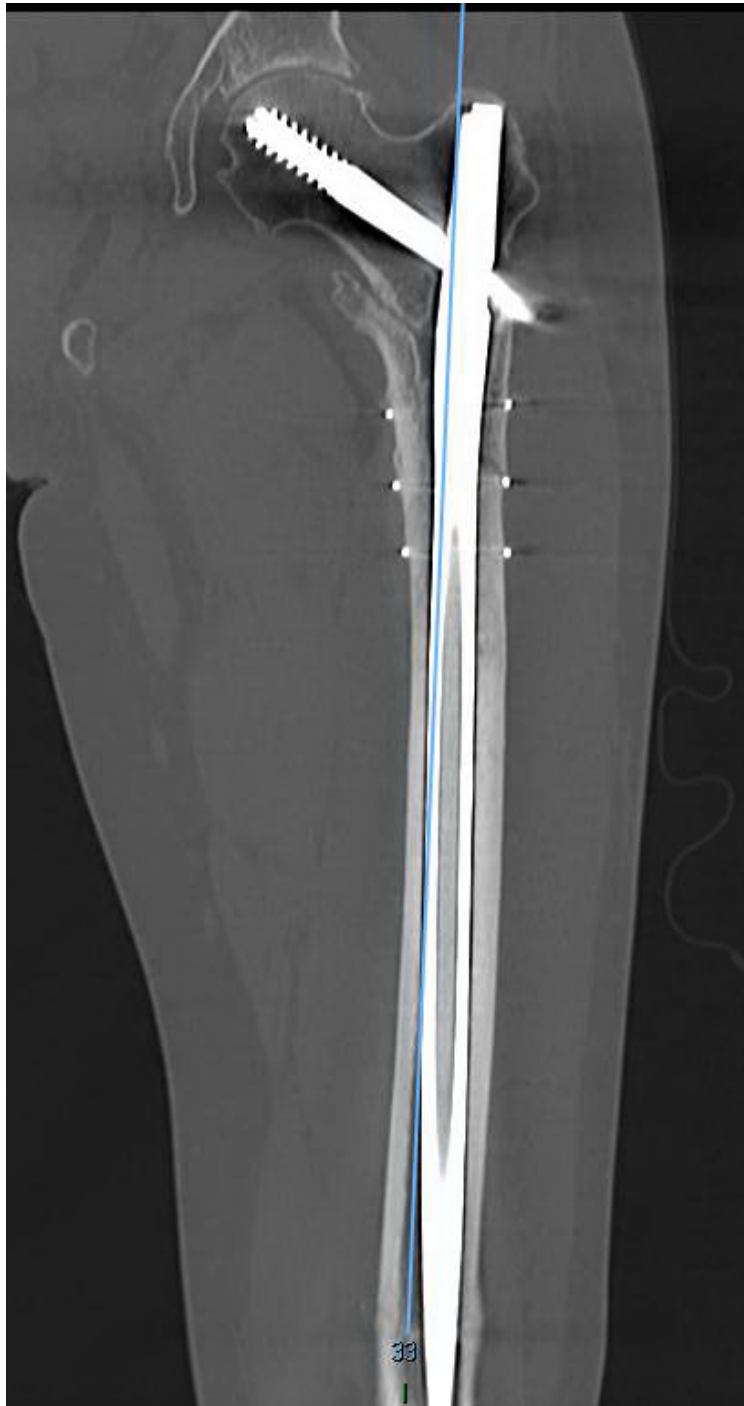
b. dynamisation

c. bone grafting



5 months post revision. Hip arthritis pain, shortening 1.5 to 2 cm. Fracture union ?

- a. Yes b. Unsure, I would like to have a scanner c. No



Not healed (6 months
post revision)

Pain

Shortening 2 cm

What to do ?

- a. Bone grafting
- b. Wait and see
- c. Hip arthroplasty

