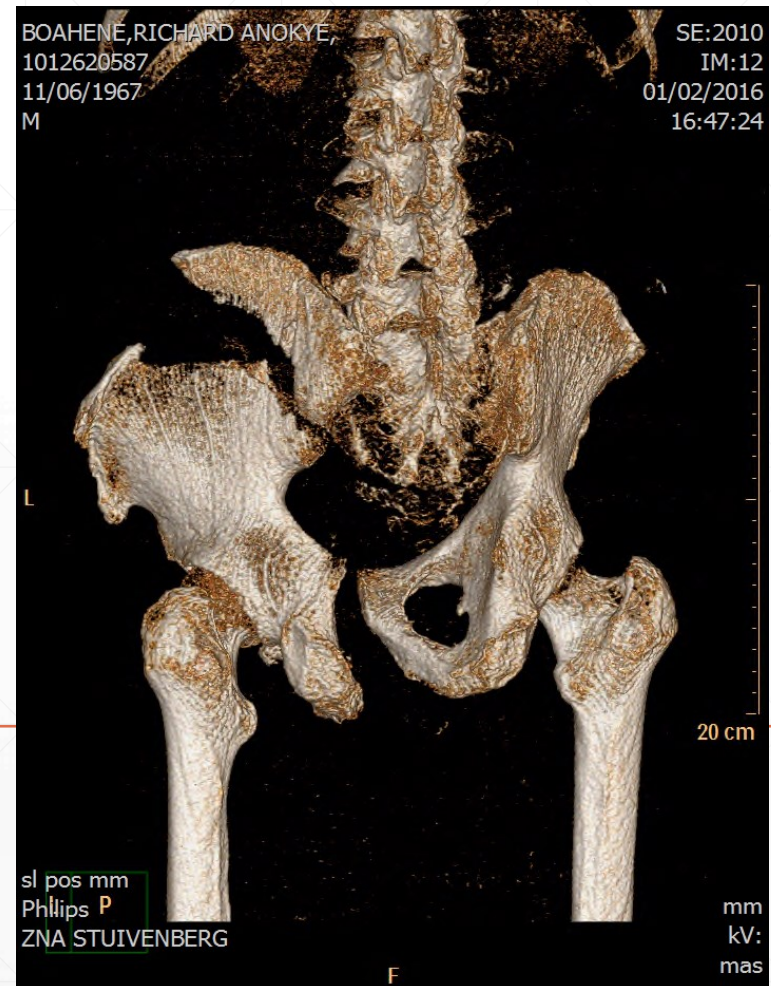
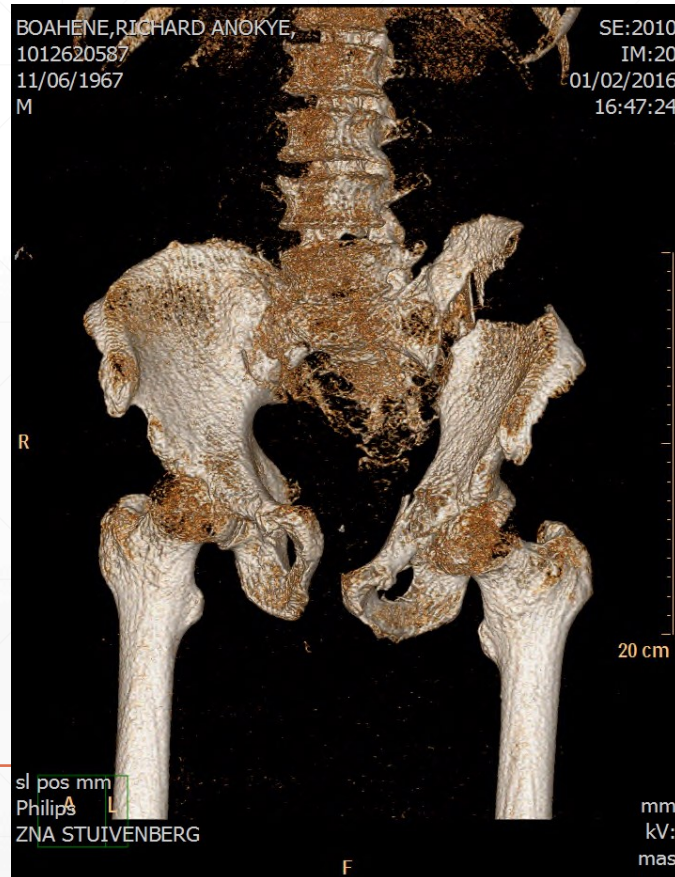


BOTA Case of the month

Dr. E. De Groof
STER Antwerpen



Pelvic trauma due to a work accident (fork-lift chauffeur : crush injury) on February 1th 2016. Patient came in in severe shock mainly due to pelvic blood loss.

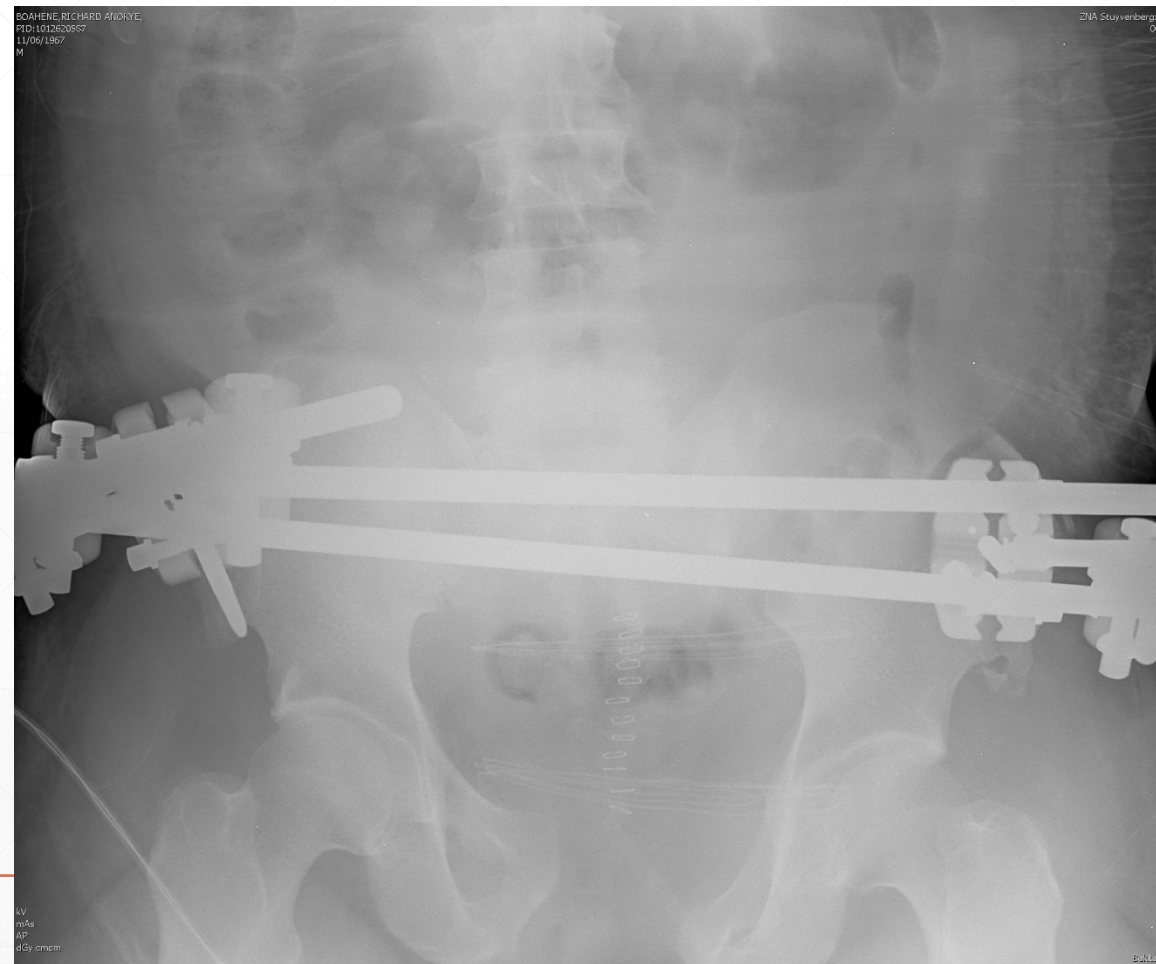


Associated injuries:

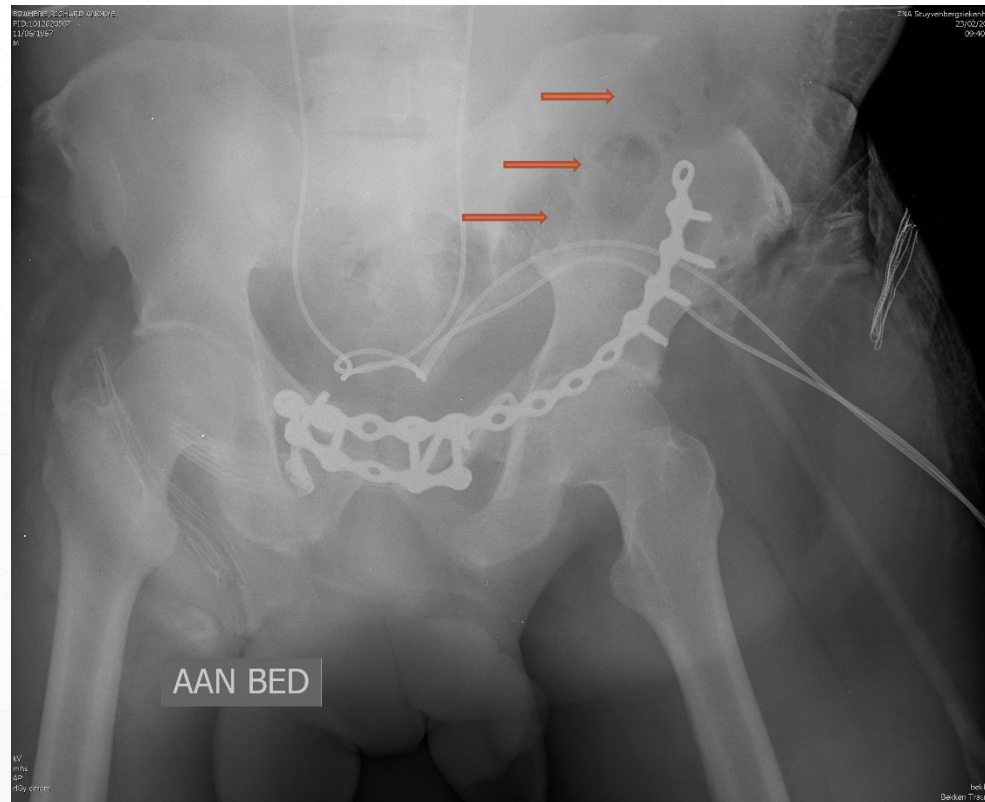
- Severe lesions of the lower plexus lumbalis,
- Complete urethra and bladder rupture,
- Thrombosis A. Iliaca externa,
- Bilateral fracture processus transversus L5,

Emergency treatment on February 1th:

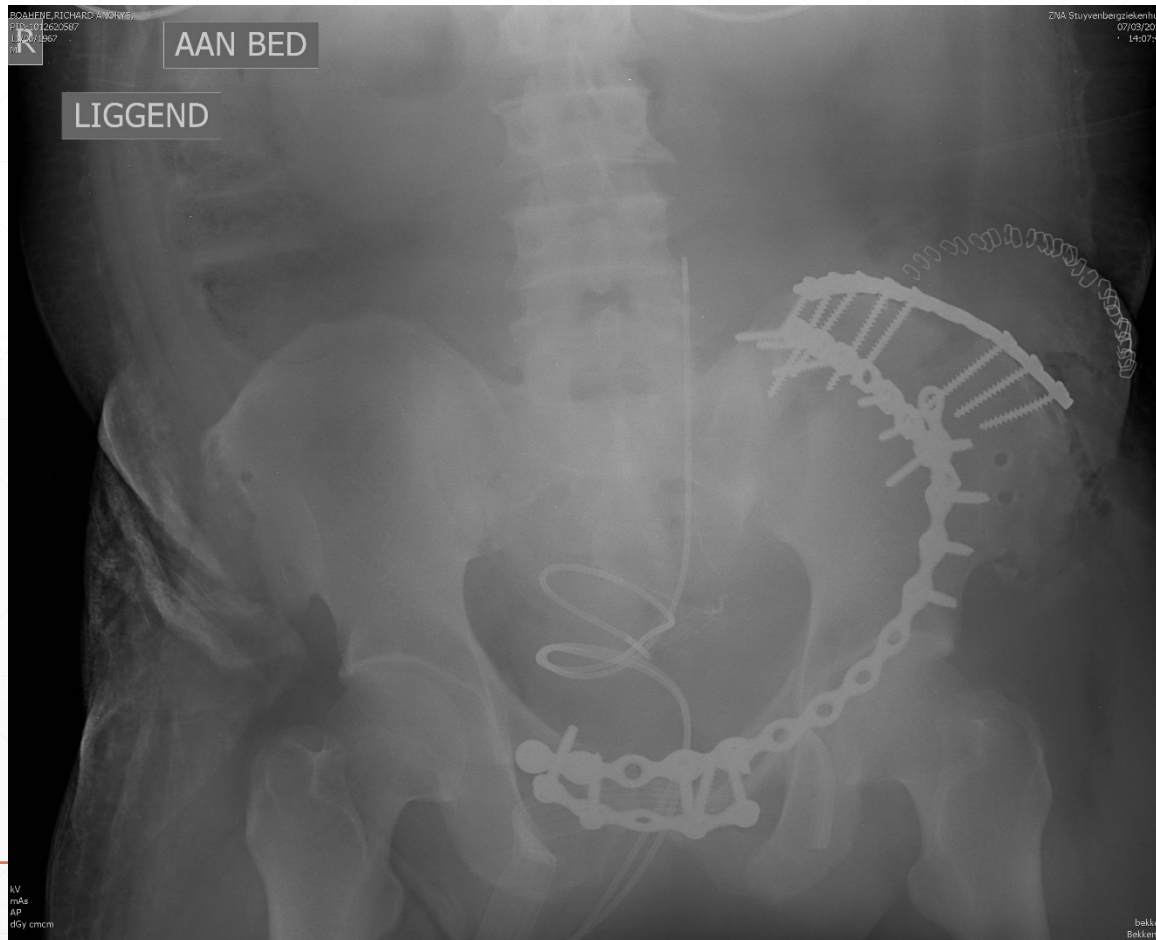
Good resuscitation,
External Fixator,
preventing left AIE and embolectomy A. Poplitea,
"ladder suture" (as good as possible!).



22Th of February: anterior fixation with plate and screws; a posterior fixation was postponed (and hoped not to be necessary) due to bad skin-wound conditions and the chronic drainage of urine via pelvic drain. However: in vain.



3Th of March: double plate fixation ilium.



Other operations

- Transurethral drainage and bilateral catheterisation of the ureters (February 22nd),
- Embolisation left A. Iliaca Interna for internal hemorraghe (29th of February),
- Tracheotomy (11th of March).

Secondary complications:

- Critical Illness Polyneuropathy and –Myopathy,
- ARDS,
- Acute renal failure,
- Gastroparesis-ileus,
- Conjunctiva infection, as well bacterial as herpes,
- Secondary AHT.

Actual Status:

- Patient is on the revalidation ward. He wears braces for the left lower leg.
- Some sort of Bricker bladder reconstruction still has to be planned.